

## Case Report

### Importance of Microfilariae Detection on Night's Peripheral Blood Smear Without Eosinophilia in a Febrile Case with Right Lower Limb Swelling

Shweta S Joshi<sup>1</sup>, Bhushan M Warpe<sup>1</sup>, Bhavin S Sharma<sup>1\*</sup>

<sup>1</sup>Department of Pathology, Gujarat Adani Institute of Medical Science, Bhuj, Kachchh, Gujarat

\* Correspondence: Dr. Bhavin S Sharma (dr.bhavin82@gmail.com)

#### ABSTRACT

Bancroftian filariasis is caused by the filarial parasite *Wuchereria Bancrofti* and is transmitted by *Culex* mosquitoes. It is found in tropical and subtropical countries. Traditionally, peripheral blood smears identify this condition by finding microfilaria. Inadvertently found adult worms and microfilaria in fine needle aspiration cytology (FNAC). The disease may be missed in the absence of eosinophilia in a CBC or peripheral blood smear. One must be aware of this possibility. Chronic inflammation and lymphedema lead to lymphatic damage, swelling and elephantiasis of the legs, arms, scrotum, breasts, and vulva. A 29-year-old male patient presented with chief complaints of pain and swelling over the right lower limb for one and a half years. It was reported to be filariasis during laboratory investigations.

**Keywords:** Filariasis, Lower limb swelling, Diethylcarbamazine

#### INTRODUCTION

Filariasis is an infectious disease caused by tiny thread-like filarial worms, which generally belong to the Filarioidea superfamily, are more common in tropical and subtropical regions and have an affinity for skin and subcutaneous tissue or lymphatic systems.<sup>1</sup> *Onchocerca volvulus* and *Loa loa*-like nematodes cause filariasis of the skin, while *Wuchereria bancrofti*, *Brugia malayi* and *Brugia timori* cause lymphatic filariasis in descending order.<sup>1,2</sup>

*W. bancrofti* is transmitted by the ubiquitous mosquito *Culex quinquefasciatus*, and *B. malayi* is transmitted by *Mansonia* mosquitoes in India.<sup>3</sup>

A human is a definitive host for the sexual stages to develop. Travelers are not prone to filariasis, resulting in a heavier helminth burden, so the prevalence rate increases with age.<sup>4</sup>

Bancroftian filariasis causes widespread clinical manifestations. While eosinophilia and microfilaremia usually occur in the acute phase, lymphadenopathy, lymphedema, hydrocele and elephantiasis are characteristic in the long term. Fine needle aspiration cytology (FNAC) has a major role in the diagnosis of subclinical filariasis.<sup>5</sup>

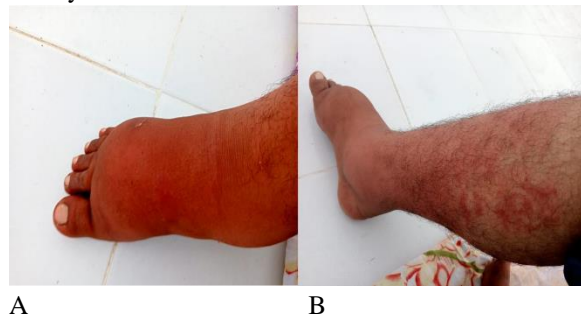
A progressive, non-pitting lymphedema with swelling of the extremities is caused by lymphatic hyperkeratosis, hyperpigmentation and sometimes elephantiasis of the lower extremities.<sup>6</sup>

#### CASE HISTORY

A 29-years-old male patient living in pakka house and working as a tailor presented with chief complain of pain and swelling over right lower limb over one and half years associated with intermittent fever.

Patient was relatively asymptomatic 1.5 years ago then he developed swelling over right lower limb following an injury to the right great toe which was slow in onset and gradually increase in size. Swelling increased in size by walking and by his tailoring job. It decreased by limb elevation and NSAID medication. A past history of trauma to the same right lower limb due to vehicular accident was noted seven years ago. No past history of DM/Hypertension/TB. There was no hydrocele or varicocele on genital examination. The migration history was not significant.

On local examination, swelling was present on the lower part of the right leg to foot with a raised local temperature. The overlying skin shows red spots and itchy skin rashes with a smooth, shiny appearance over the right lower limb and pitting oedema over the dorsum of the right foot (Figures 1- A and B). Peripheral arterial pulsations were present. No visible pulsation, dilated veins, discharge or scar was seen. The systemic examination was normal.

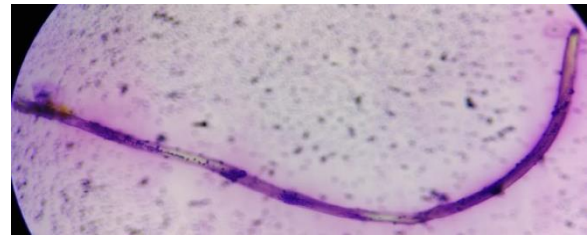


**Figure 1: Clinical photographs of Lymphatic filariasis patient. Patient had swelling with pitting oedema from lower part of right leg to foot (A) and Overlying skin shows red spots and itchy skin rashes with smooth shiny appearance over right lower limb (B).**

On arrival, all routine hematological investigations were done which were suggestive of neutrophilic leukocytosis in the complete blood cell count. USG of both inguinal regions was done, suggesting a few variably sized lymph nodes in the right inguinal region, with the largest size measuring approximately 1.1x0.7 cm. In the Doppler study, single limb (arterial and venous) showed the right lower limb with significant subcutaneous edema involving the right foot.

The patient was admitted on July 20, 2023 and managed conservatively in our hospital during treatment. On July 23, 2023, a peripheral blood smear

was conducted after a blood sample was obtained the night before the diagnosis, and the results showed microfilaria (Figure- 2). On CBC, Hb was 15.9 g%, the WBC count was 19100/cu mm and the differential count showed 90% neutrophils, 7% lymphocytes, 1% eosinophils, and 2% monocytes. The ESR determined by the Wintrobe method after one hour is 42 mm. Bacterial analysis showed that microfilariae had a hyaline sheath, a cephalic space, and a tail end devoid of nuclei on microscopic examination. Thus, it confirmed *Wuchereria bancrofti*.



**Figure-2: Peripheral blood smear examination showing Microfilaria (Giemsa stain, x 1000)**

The patient was given 100 mg of diethylcarbamazine (DEC) orally, along with antibiotics, analgesics and other supportive measures. During the treatment, the patient's hemodynamics remained stable and his fever improved. The patient was discharged on medication on 24/7/2024 with follow-up advice and necessary instructions to prevent mosquitoes by using mosquito nets and repellents, as this may lead to disease progression.

## DISCUSSION

Filariasis is a parasitic disease caused by the presence of microfilariae in the embryonic stage between eggs and larvae. These are free-living, uncoiled embryos that have features seen in larvae and have still not developed the gut. Microfilaria are labelled as sheathed or unsheathed based on the presence of egg shell.<sup>7</sup> This feature and nuclear arrangement, particularly in the tail end, help to distinguish between the different species of filarial worm.<sup>8</sup>

Lymphatic filariasis is a disease caused by nematodes (*W. bancrofti*, *B. malayi* and *B. timori*) that are transmitted by mosquitoes. The life cycle of *Wuchereria Bancrofti* consists of two species: humans (definitive host) and mosquitoes (intermediate host). Pregnant females secrete significant amounts of microfilariae, which are released into the lymph nodes by adult worms. These larvae pass through the thoracic

duct and pulmonary capillaries into the peripheral circulation.<sup>9</sup> Adults can survive in the lymphatic system for 5 to 15 years.<sup>10</sup>

The 'gold standard' method for diagnosis of infection due to *W. bancrofti* is a test that detects circulating filarial antigens.<sup>11</sup> However, a peripheral blood smear obtained overnight during a fever may be helpful in detecting microfilariae. This requires rapid decision-making by clinicians and pathologists.

A definitive diagnosis of lymphatic filariasis can be made by testing microfilariae or filarial DNA in the blood, detection of *W. bancrofti* virus alone in lymphatics or detection of filarial antigens circulating in the bloodstream of the infected adult.<sup>12</sup> Our patient was not willing to undergo FNAC or a biopsy because of his foot swelling or a palpable inguinal node. A high level of suspicion is required to diagnose filariasis in this setting and peripheral smears often lack eosinophilia and infection.<sup>13</sup> The absence of microfilariae in peripheral blood smears excludes filarial infection.

Eosinophilia is abundant in peripheral blood smears and may exceed 3000/ $\mu$ L.<sup>14</sup> In our case, microfilarial organisms in the night blood sample were detected in the absence of eosinophilia. The incidence of filariasis-induced eosinophilia in endemic areas is difficult as it may be associated with other helminth infections in humans.<sup>12</sup>

Recent advances include membrane filter techniques for the detection of microfilariae, ultrasound and lymphoscintigraphy in diagnosis.<sup>15</sup> Adult worms migrating in the lymphatic vessels ("filarial dance sign") can be detected and the effectiveness of treatment can be monitored by using ultrasonography.<sup>16</sup>

Fine needle aspiration cytology examination (FNAC) proves to be an important investigation in patients with the presence of palpable swelling with a difficult clinical diagnosis and when the blood picture does not show evident microfilariae or eosinophilia. Microfilariae can be present in the breast, thyroid, liver, and lungs.<sup>17</sup> In our case, no such swellings were noted for FNAC or biopsy.

Monoclonal antibodies against circulating filarial antigens and molecular biology techniques such as fluorescence in situ hybridization (FISH), in situ hybridization (ISH), and polymerase chain reaction (PCR) are now available for specific diagnosis only in

specialized locations.<sup>18</sup> This was not done due to cost restraints in our case.

The drug of choice contains diethylcarbamazine (DEC) for the treatment of lymphatic filariasis. DEC has a significant lethal effect on lymphatic filariasis but has no effect on the development of intramosquito microfilariae or the third-fourth stage of larvae of *W. bancrofti*. Other treatment options include surgery and other excision techniques in cases of worsening conditions.<sup>19</sup>

Few modalities that help to prevent further progression of swelling are<sup>20</sup>:

- ✓ Keeping the limb elevated at night, after removing the bandage.
- ✓ When ambulant, use elasto-crepe bandages or specially made stockings.
- ✓ Regular physiotherapy exercises for the affected limb.
- ✓ Regular light massages to stimulate the lymphatic system, especially in the early stages of oedema.
- ✓ Single or multicell jackets used during intermittent pneumatic compression of the affected limb.
- ✓ Using moist heat or hot ovens in heat therapy.

## CONCLUSIONS

The diagnosis of filariasis requires a high level of suspicion with an intention of finding microfilaria in peripheral blood, preferably in night blood samples especially when eosinophil count is normal with neutrophilic leucocytosis and the ESR is high. Diagnostically, FNAC plays a key role in clinically palpable superficial lesions in willing patients. In asymptomatic patients, ultrasound/color doppler plays a diagnostic role in finding out moving adult worms in lymphatic vessels. With the knowledge of filarial vectors, an effective diagnostic tool, treatment with effective follow-up and a lack of animal hosts, filariasis is certainly a treatable disease.

## REFERENCES

1. Shenoy RK. Clinical and pathological aspects of Filarial lymphedema and its management. *Korean J Parasitol.* 2008;46(3):119-25.

2. Oza H, Bhalodia J, Shah A, Modi P. Mid arm swelling-A rare presentation of Filariasis. *Natl J Med Res.* 2014;4(3):256-8.
3. Bumay. Prospects of elimination of lymphatic filariasis in India. *ICMR Bull.* 2002;32:5-6.
4. Evans DB, Gelband H, Vlassoff C. Social and economic factors and the control of lymphatic filariasis: a review. *Acta Trop.* 1993;53(1):1-26.
5. Akhtar S, Gumashta R, Pande S, Maimoon S, Mahore S. Cytodiagnosis of filarial infection on a non healing ulcer: An unusual presentation and review of literature. *Prog Health Sci.* 2012;2:195-9.
6. Radhakrishnan K, Rockson SG. The clinical spectrum of lymphatic disease. *Ann N Y Acad Sci.* 2008;1131(1):155-84.
7. Gutierrez Y. Filaria of the lymphatics. In: *Diagnostic Pathology of Parasitic Infections with Clinical Correlation.* New York: Oxford University Press; 2000. p. 433-4.
8. Gutierrez Y. Nematode morphology. In: *Diagnostic Pathology of Parasitic Infections with Clinical Correlation.* New York: Oxford University Press; 2000. p. 273-6.
9. Kanade US, Dantkale SS, Chaware SA, Narkhede RR, Gadhekar MS. Microfilaria in preauricular subcutaneous nodule on cytology: An unusual presentation. *J Evol Med Dent Sci.* 2012;1:382-6.
10. Ridley JW. Blood (Intracellular) and other protozoa. In: Ridley JW, editor. *Parasitology for Medical and Clinical Laboratory Professionals.* USA: Delmar; 2012. p. 96-104.
11. Agarwal VK, Sashindran VK. Lymphatic filariasis in India: Problems, challenges and new initiatives. *Med J Armed Forces India.* 2006;62(4):359-62.
12. Rocha A, Braga C, Belém M, Carrera A, Aguiar-Santos A, Oliveira P, et al. Comparison of tests for the detection of circulating filarial antigen (Og4C3-ELISA and AD12-ICT) and ultrasound in diagnosis of lymphatic filariasis in individuals with microfilariae. *Mem Inst Oswaldo Cruz.* 2009;104:621-5.
13. Ottesen EA, Duke BO, Karam M, Behbehani K. Strategies and tools for the control/elimination of lymphatic filariasis. *Bull World Health Organ.* 1997;75(6):491-503.
14. Owusu-Agyei AK, Nabarro L. Helminth infections and differentials of eosinophilia. *Medicine.* 2021;49(12):766-9.
15. Anitha K, Shenoy RK. Treatment of lymphatic filariasis: Current trends. *Indian J Dermatol Venereol Leprol.* 2001;67:60-5.
16. Chaubal NG, Pradhan GM, Chaubal JN, Ramani SK. Dance of live adult filarial worms is a reliable sign of scrotal filarial infection. *J Ultrasound Med.* 2003;22(8):765-9.
17. Andola SK, Naik AA. Microfilaria and filarial granulomas from fine needle aspirates: a study of 25 cases. *Southeast Asian J Trop Med Public Health.* 2011;42(6):1351-8.
18. Haleem A, Al Juboury M, Al Hussein H. Filariasis: A report of three cases. *Ann Saudi Med.* 2002;22:77-9.
19. World Health Organization. Lymphatic filariasis: the disease and its control. 5th report of the WHO expert committee on filariasis. Geneva: WHO; 1992.

20. Pani SP, Lall R. Clinical features, pathogenesis and management of lymphatic filariasis. ICMR Bull. 1998;28:41-51.

**Source of support:** Nil.

**Conflict of interest:** None

<p><b>How to cite:</b> Joshi SS, Warpe BM, Sharma BS. Importance of Microfilariae Detection on Night's Peripheral Blood Smear without Eosinophilia in a Febrile Case with Right Lower Limb Swelling. GAIMS J Med Sci 2024;4(2):42-46.</p> <p><a href="https://doi.org/10.5281/zenodo.11445024">https://doi.org/10.5281/zenodo.11445024</a></p>
--